



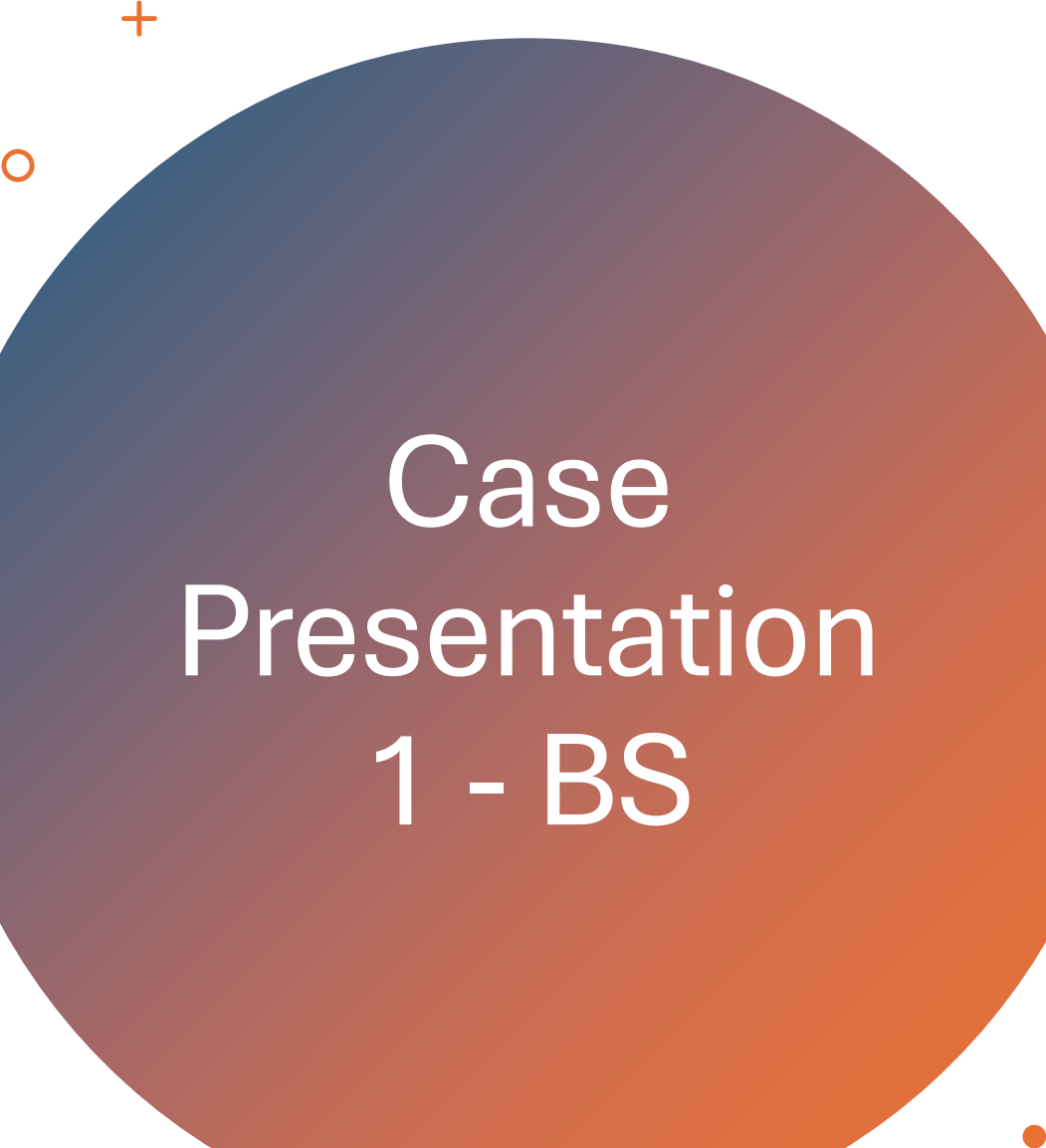
# GOJ cancers – systemic therapy A tale of 2 diseases – what next?






# Introduction

- 2 very different cases of a similar disease divided by histology
  - This is a common and devastating disease for our patients
  - With a lack of access to targeted agents, including immunotherapy, our armamentarium is very limited to treat these patients
  - In South Africa – it is one of the leading causes of cancer related deaths (2<sup>nd</sup>)
  - Lack of options especially second line
- 




# Case Presentation 1 - BS

- 54yr old female
  - Presenting with a 9/12 history of progressive dysphagia
  - LOW of weight (10kg)
  - Constitutional symptoms – fever and malaise
  - At time of presentation – able to tolerate a soft ward diet
  - Diagnosed via gastroscopy with a squamous cell cancer of the oesophagus
  - Referred to oncology service via MDT from upper GI surgery unit for definitive CCRT
- 




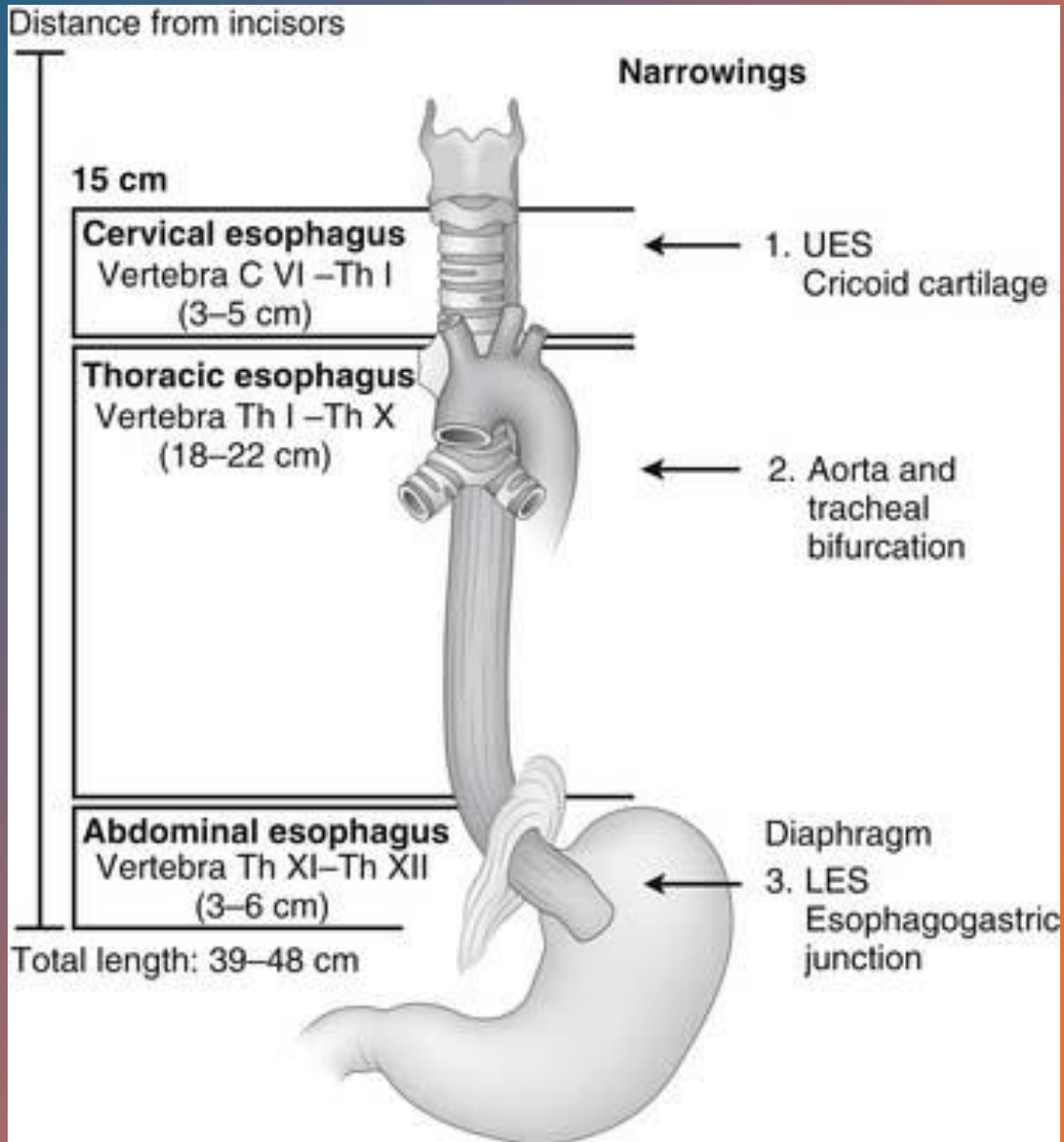
# Further history

- Previous PTB 2007 – sputum diagnosed and treated for 6 months
  - HIV reactive on treatment since 2010 – TDF/XTC/DTG
  - VL LDL CD4 500
  - Non smoker
  - Social ETOH usage very occasional
  - No family history of cancer
  - No occupational exposures
- 



# Clinical examination

- Weight 82kg
  - ECOG 01
  - Vitals stable
  - No other relevant clinical findings
- 

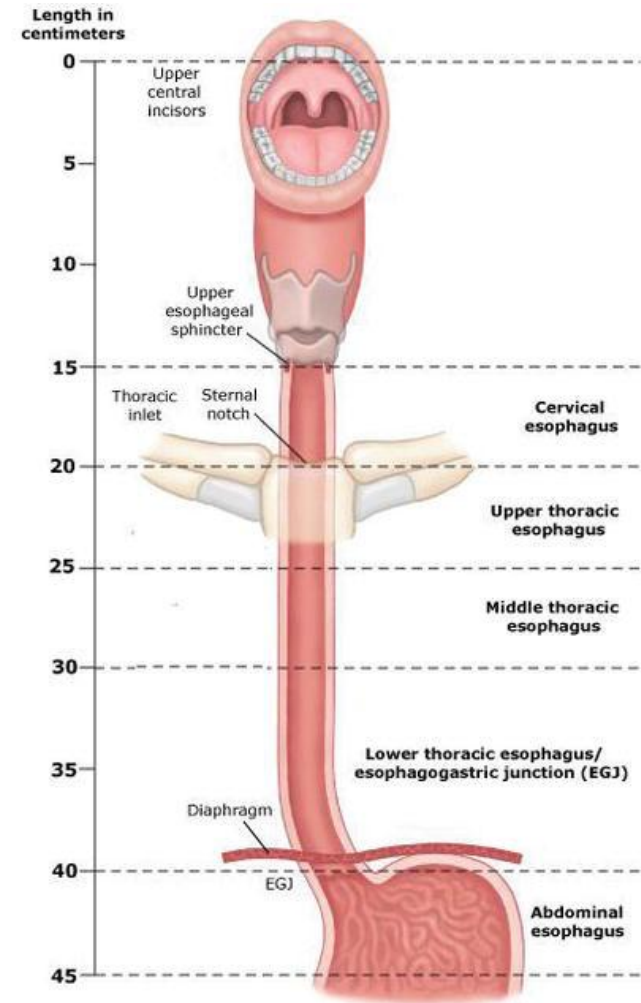


# Investigations

- Barium swallow: Oesophageal rat tail stenosis in distal 1/3 with prox dilatation
- Distal oesophageal mucosal irregularity
- Gscope: Oesophageal ca at 25cm (long segment distal oesophagus malignant lesion)
- Due to resource constraints, PET CT is not available to us and EUS is not done routinely
- Histology: Focal representation of an invasive moderately differentiated keratinizing squamous cell carcinoma


# CT SCAN – Chest and abdomen

- Hyperdense concentric lesion (mass-like) extending from T5 to T12 level
- Nodular thickening of GOJ wall
- Lesion abuts but is separable from posterior margin of the carina and central bronchi, descending thoracic aorta, and posterior margin of the left atrium
- Lymph node burden: L para oesophageal AP 32 x 22mm abutting main pulm artery but separable
- RLL lung nodule (subcm 9x4mm) – thought to be related to asp pneumonitis
- UL tree in bud nodules Left
- **T3N1M0 Squamous cell carcinoma oesophagus**






# Radiation oncology treatment

- Concurrent cisplatin 70mg/m<sup>2</sup> 3 weekly IVI
  - Capecitabine 800mg/m<sup>2</sup> D1-5po
  - 2Gy – 50Gy EBRT completed with no treatment interruptions
  - CCRT definitive
  - Completed Jan 2024
  - A repeat CT scan was done post therapy March 2024
  - Stable disease was noted but the disease still not operable as per surgical assessment
- 



# MDT presentation

- ECOG 1
  - No significant LOW (still weighs 80kg)
  - Not amenable to surgery
  - Still able to swallow and with very minimal symptoms
  - The decision was made to assess for further chemotherapy in the 'hopes of eventual resectability'
  - She had also been referred to supportive care services , including palliative care and dietician
- 

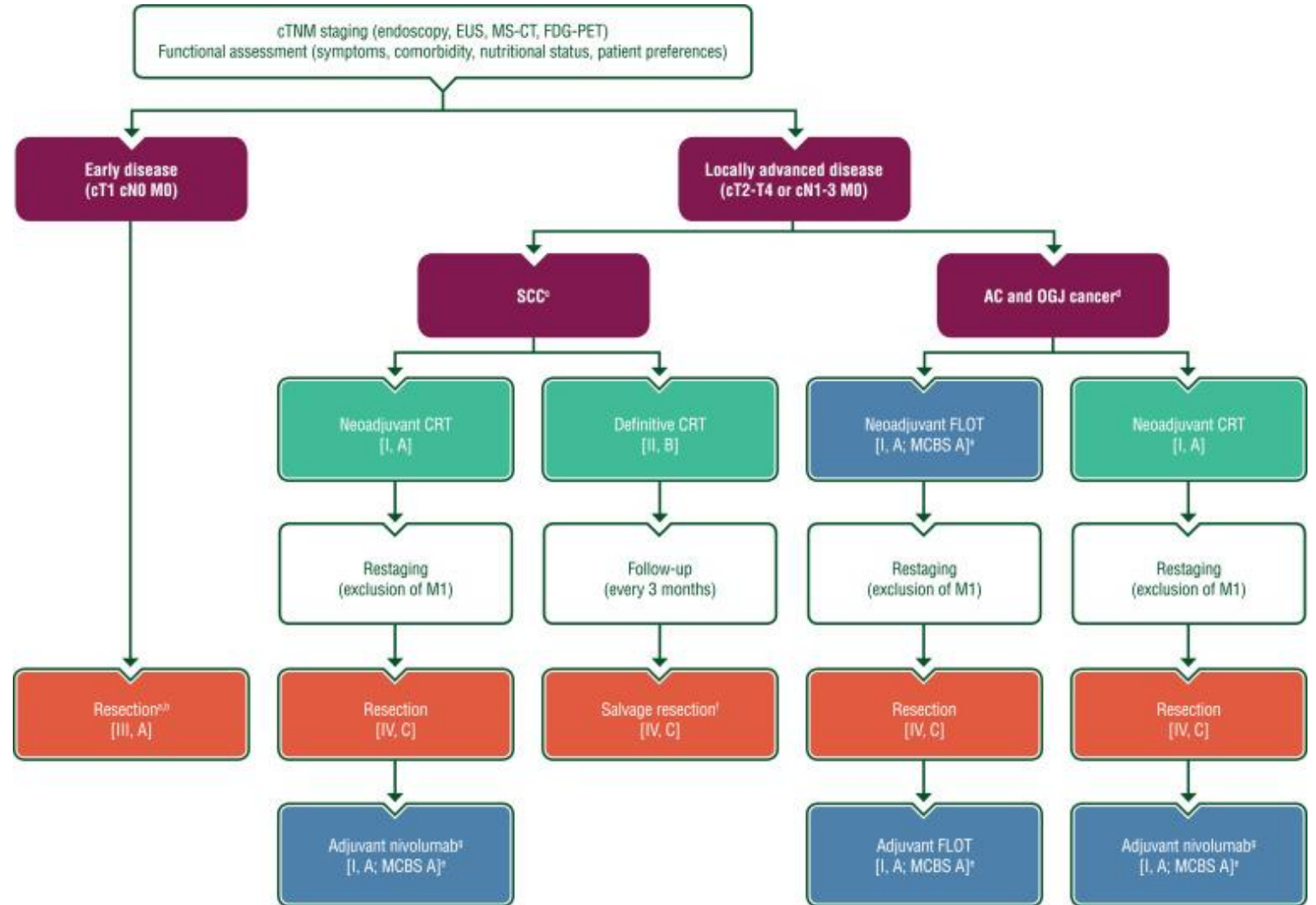


# Questions

- What options are now available to patient ?
- If salvage surgery is not possible – what can be done?
- Minimal evidence
- Cytotoxic chemotherapy very limited
- No access to Nivo in South African state hospitals
- ?surgical options which would be feasible


# GUIDELINES

---





# Case 2 LD

- 64yr old male
  - Complaining of LOW 20kg and dysphagia to solids
  - He was scoped and dilated by the surgical team on presentation due to an obstructive mass
  - Referred with metastatic GOJ adenocarcinoma (Siewert 2)
  - Extensive primary
  - Past med hx: strong smoking history, denied alcohol
  - Fam Hx: None
- 




# Investigations

- Histology: Invasive moderately differentiated adenocarcinoma
- Gscope : Fungating mass extending from gastric cardia
- CT Scan: diffusely thickened gastric cardia and fundus with prox dilatation of the oesophagus
- Invades through the serosa with no plane of separation
- Mets – splenic focal hypodensity
- Large superior gastric node suprarenal and adjacent to the adrenal gland (retroperitoneal) – matted to the superior aspect of the stomach
- **T4N1M1 – advanced gastro oesophageal cancer**




# History continued

- Patient was referred to medical oncology for chemo assessment via MDT
- ECOG 1 but underweight at 32 kg
- Also referred to nutritional and supportive care teams
- Patient was counselled and opted to start chemotherapy with a palliative intent
- He was now able to swallow post stent and dilation
- CAPEOX ( Capecitabine 850mg/m<sup>2</sup> for 2 weeks and Oxaplatin 130mg/m<sup>2</sup> D1 of a 21 - day cycle)
- Aimed for 6 cycles and then a rescan to assess for response




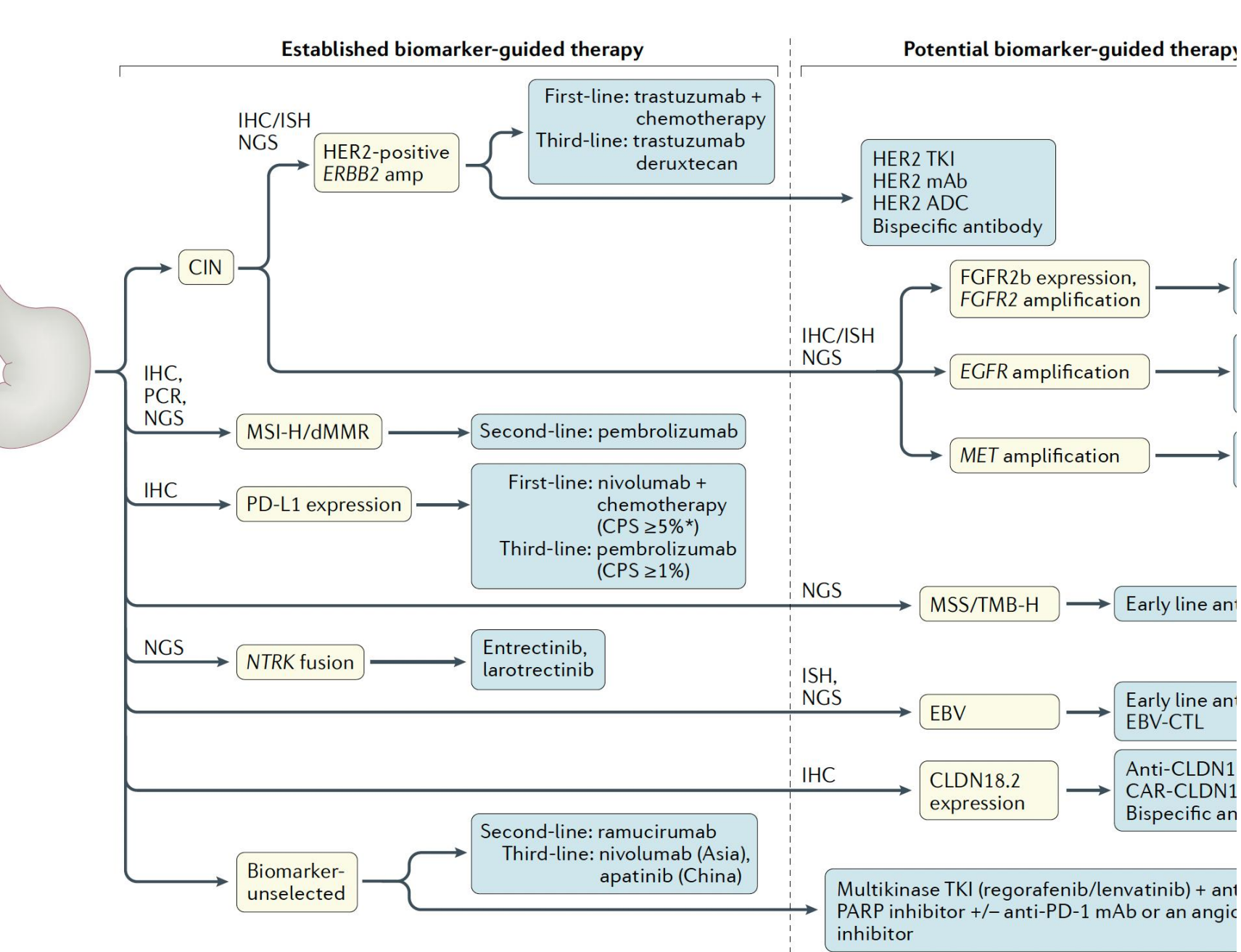
# CT response (post 6 cycles therapy)

- Locally aggressive disease with direct spleen invasion – with reduction in size
  - Large nodal mass in retroperitoneum has decreased significantly in size
  - Still abuts adrenal gland
  - GOJ lesion has significantly decreased in size with resolution of stenosis and reflux previously seen
  - CT nodal mass decreased from 45x46x48mm to 8.7x16.9x14.9mm
  - The splenic lesion has halved in size
  - No distant mets
- 



# Case continued

- Patient gained weight – now weighing 58kg with improved muscle mass
  - Able to swallow
  - Excellent response to therapy
  - Minimal side effects Grd 1-2 HFS with some mild myelotoxicity
- 




# Biomarkers

- Potential targets



# Questions

- What now?
  - Still advanced disease but more local invasion than metastatic spread
  - Pt ECOG 0-1 would be fit for surgical procedures
  - Second line chemotherapy
  - How to judge the initial lesion
  - ?RT
- 

# References

- ESMO Guidelines
- NCCN Guidelines
- Nakamura, Yoshiaki, Akihito Kawazoe, Florian Lordick, Yelena Y. Janjigian, and Kohei Shitara. 'Biomarker-Targeted Therapies for Advanced-Stage Gastric and Gastro-Oesophageal Junction Cancers: An Emerging Paradigm'. *Nature Reviews Clinical Oncology* 18, no. 8 (August 2021): 473–87.  
<https://doi.org/10.1038/s41571-021-00492-2>.